



AGE DETERMINATION

Aim

The aim of this guide is to provide information on how the progress of tooth eruption and wear may be used as a method to assist managers in estimating the approximate age of deer.

Reasons for ageing

- ◆ To assess the impact of culling on population structure.
- ◆ To provide information on the age structure of the population.
- ◆ To estimate the approximate age of a trophy for clients.

Accuracy of ageing methods

The teeth of deer take a specific, definite time to grow but will wear over a less predictable time. The time taken to grow will depend on the species of deer, whereas tooth-wear will depend on factors such as the sex of the individual (males generally have higher wear rates than females) as well as the food plants the animal is feeding on.

Methods of ageing deer are based largely on tooth eruption patterns and the degree of wear on teeth. Alternative methods involve cross-sectioning the tooth to examine layers of dentine (equivalent to age-rings in trees). This method is more time-consuming, and requires teeth extraction from the jaw.

All methods of jaw or teeth ageing are subject to difficulties in accurately estimating the precise age. What can realistically be achieved is to arrive at an age-class estimate as opposed to a specific year.

Where locally obtained known-aged jaws are available to deer managers to allow comparison, it may be possible to make more detailed estimates of age within those broad categories.

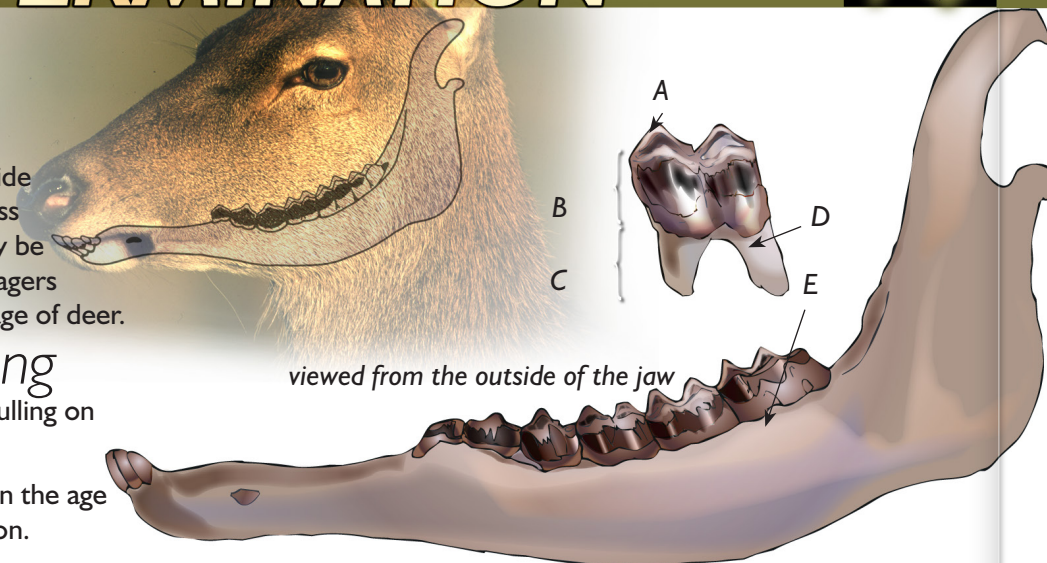
Teeth anatomy: adult jaw

Adult jaw

There are 6 'cheek' teeth in the jaw of an adult deer. For identification purposes these are divided into pre-molars (PM) and molars (M). The pre-molars of an adult deer have one or two cusps, whereas in calves, pre-molar three (pm iii) has three cusps.

Teeth anatomy: eruption

In juvenile deer, the front three pre-molars (commonly known as milk teeth) are deciduous i.e. they



- A. Cusps. These are the highest points of the crown. They provide effective shearing surfaces to enable the deer to break down fibrous vegetation and will become worn down with age. Crests are lower on the outer side of the jaw — examine from this side
- B. Crown. Hard, smooth enamel, stained where exposed above the flesh of the gum and white below
- C. Root. Yellow, matt, and softer than the crown
- D. Root-crown junction. As the deer ages this emerges from the jawbone. Where it has emerged it can be felt as a ridge when scraped with a fingernail, as well as identified by the change in appearance. Good light is required and a knife should be used to lever the tooth slightly, to provide a clearer view. The root-crown junction emerges on each tooth at different ages
- E. Topline of jawbone.

are only temporary, and are shed during the first three years (depending on species) when they are pushed off and replaced by the permanent pre-molars as they emerge from below. Because tooth eruption is consistent between individuals of the same species, age and between locations, this is the primary means for age assessment, backed up by wear criteria.

Eruption progress

The pattern of eruption and replacement of the temporary (deciduous teeth) is predictable for all deer species, however, the time taken to achieve a full mouth of permanent teeth will vary between species.

- ◆ Red, sika and fallow deer
The progress of tooth eruption is similar in red, sika and fallow deer and will take 30 months to reach a full mouth. The third molar begins to emerge at two years of age.
- ◆ Roe deer
Compared to other deer species, tooth eruption is much earlier in roe deer with a full mouth being achieved when the deer is approximately 13 months old.

Tooth wear

1. **Infundibulum:** In young deer very distinct and quite literally cavernous, extending the full depth of the crown (fig. 3). In older deer the surrounding enamel becomes worn down, and eventually the location of the infundibulum may only be indicated by darker coloration or disappear entirely (fig. 4).

2. **Dentine:** Either side of the infundibulum are two layers of brown dentine, each surrounded by paler enamel. With wear, the enamel is worn down, causing the strips of dentine to become wider and longer; eventually they join at either end of the tooth and encircle the infundibulum (fig. 4).

Procedure

Red, sika and fallow:

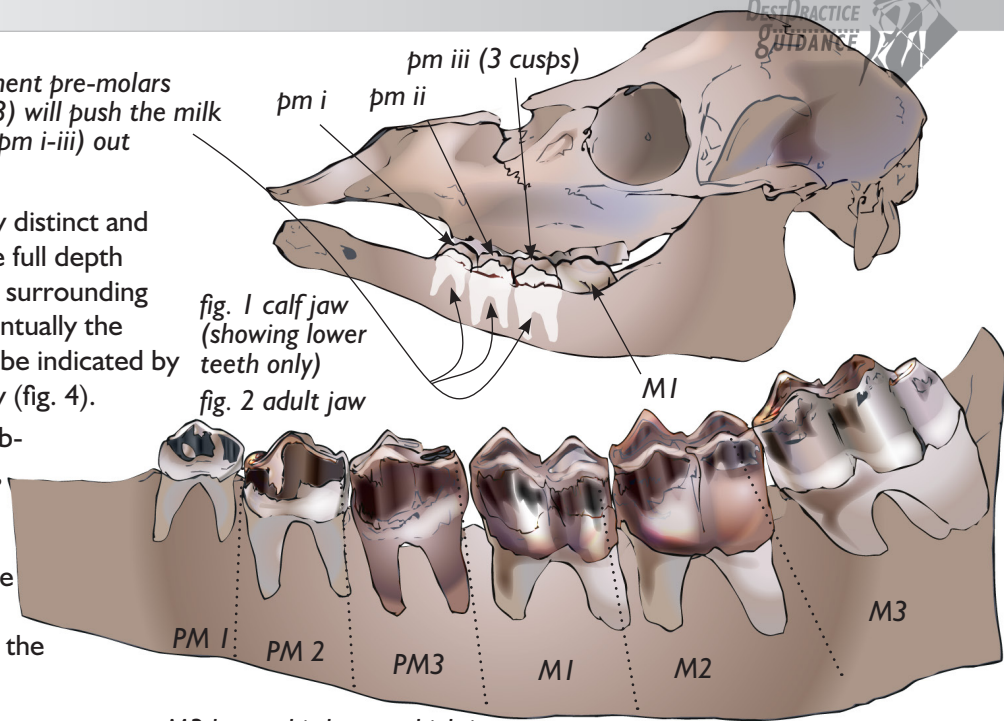
3 Use the following to identify the approximate age bracket.

Age class	Eruption	Wear
0–24 months	'calf'. M1 emerged. 'yearling' M1 & M2 present. All pre-molars are temporary teeth.	None.
2–4yrs	Six adult teeth. Root-crown Junction not visible on M2 or M3. All crowns evenly stained with tartar.	Slight wear on outer edge of cusp of M1 and M2. A continuous line of dentine is beginning to form a ring around the infundibulum on M1.
5–7 yrs	Root-crown Junction is now visible above the level of the jaw bone on all teeth.	No or slight wear on third cusp of M3. Dentine is exposed along the full length of all cusps. Infundibula are completely surrounded by dentine on M2. The brown dentine is broader than the white enamel on all crowns.
8yrs +	Root-crown Junction is at least 1mm above the jaw bone on all teeth.	All infundibula are now surrounded by a ring of dentine. No cusps remain on any teeth above the level of the pulp cavities. The height of the crown is equal to or less than the height of exposed root in all teeth.

Roe:

Note that wear of roe deer teeth is faster than that of red: for example, molar tooth wear in 3-year-old roe may compare to that of 6-year-old red.

permanent pre-molars (PM1-3) will push the milk teeth (pm i-iii) out



M3 has a third cusp which is smaller and at the rear, not to be confused with 3 cusps of pmiii (see fig. 1)

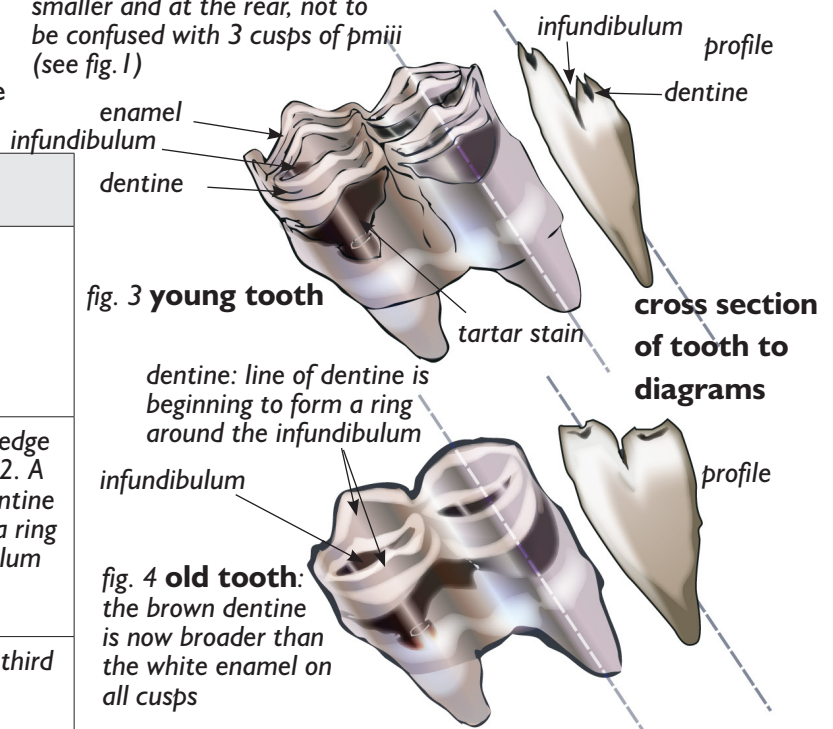


fig. 3 young tooth

fig. 4 old tooth:

the brown dentine is now broader than the white enamel on all cusps

3 Use the following to identify the approximate age bracket.

Age class	Eruption	Wear
0–13 months	Temporary teeth in process of being replaced.	Little wear on any of the molars.
14 months–4yrs	Six adult 'cheek' teeth.	Slight wear on outer edge of cusps of all molars.
5–7 yrs		Further wear on outer edge of cusps of all molars and wear on crest.
8yrs +		Surfaces of molars flat, M1 and M2 may be worn down to the level of the gums.