



## BUTCHERING(2)

continued from Butchering(1)

### Splitting the aitch bone

- 3** Using a steak knife cut exactly in the centre of the two haunches onto the pelvic bone, exert some pressure on the knife. In a young animal the aitch bones will divide through the cartilage. On older animals a saw will be needed to part the two haunches (fig.1). Make sure that if a saw is used all bone dust is removed from both surfaces.

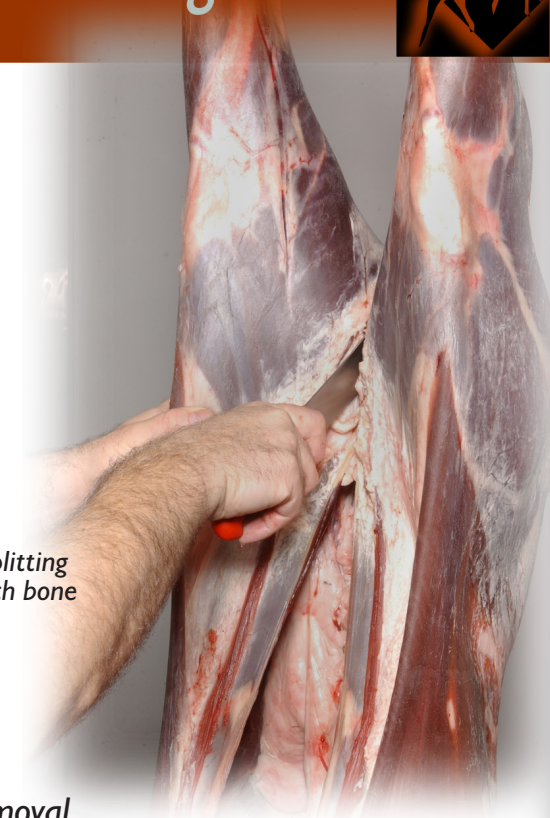### Breakdown of the hindquarters

- 3** The following processes are carried out on the cutting table for ease of operation.

fig.2 flank removal




fig. 1 splitting the aitch bone



### Flank removal

- 3** The first part of the operation involves the removal of the flanks. Make a cut parallel to the backbone of the carcass to finish at the ribs – the length of the ribs can be decided by the size of the carcass. This is indicated by the dotted lines (fig.2).
- 3** Make the ribs longer so that the loins may be rolled into joints at a later stage if required or cut shorter for steaks. Repeat the process on the other side.

### Kidney and suet fat removal

- 3** The kidneys and fat surrounding them is removed carefully by easing away the suet from the abdominal cavity, take extreme care not to cut into any underlying muscles when carrying out this operation.

### Tenderloin removal

- 3** To enable the carcass to be broken down into haunches and a saddle the tenderloins are removed completely first.
- 3** Cut around the head of the tenderloin and cut away from the pelvic bone.
- 3** To remove the tenderloins follow the vertebrae on each side of the carcass to remove completely intact (fig.3). The lumbar vertebrae have 'T' bones that are exposed when the tenderloins are removed.



fig.3 tenderloin removal



**Saddle removal**

**3** The saddle is prepared using a sheet boning method to remove the striploins from each side of the vertebrae. Care must be taken to ensure that the knife is always pressed onto the ribs (fig.4).




fig.4 working on the saddle: maintain knife pressure on ribs

**Haunch removal**

**3** Situated on top of the pelvic cavity the point where the sacrum (tail) is connected to the aitch bone is a fused joint. This can be opened by inserting a boning knife at the angle demonstrated (fig.5). Follow the division towards the tail area and the haunch falls away.

**3** Cut around the end of the aitch bone as shown (fig.6 & 7). The process is then repeated on the other side to remove the opposite haunch.

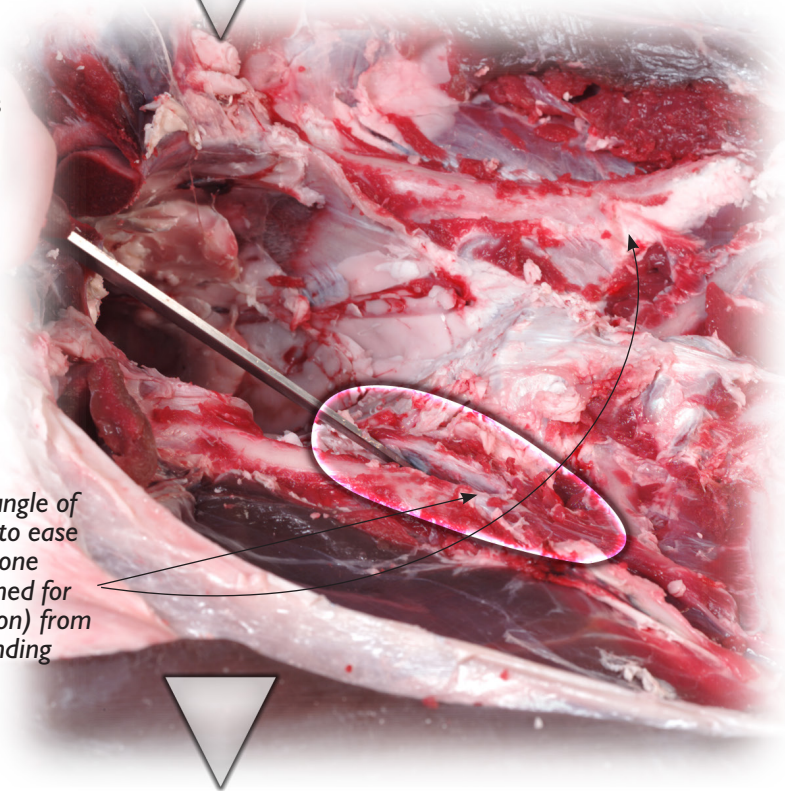


fig.5 note angle of knife used to ease the aitch bone (here outlined for identification) from the surrounding sacrum

continued in Butchering(3)

(fig.6 & 7) following the division of the haunch and aitch bone towards the tail area and the haunch will fall away (far right)

